Viora's PCR™ Technology Further Enhances the Efficacy of Long Pulse Nd:YAG Laser

Cruzy Tagger (M.D.) and Inna Belenky (Ph.D.)

Key words: *Long Pulse Nd:YAG laser, vascular lesions, Hair removal, Skin rejuvenation*

ABSTRACT: ***Introduction****: The 1064 nm Neodymium-YAG laser have been widely used for hair removal, treatment of vascular lesions, skin photo-rejuvenation and more. Development of the long pulsed Nd:YAG technology has enabled delivery of macropulses, consisting of a series of synchronized sub-pulses which is believed to decrease the collateral thermal. The aim of this study was to investigate the safety and efficacy of Pulse ConfiguRhythm (PCR™) technology with both Single and Multiple pulse configurations as incorporated in Viora's V-Nd:YAG handpiece.* ***Materials and Methods****: A group of 31 volunteer patients were treated with the V-Nd:YAG handpiece which also incorporates changeable spots and integrated contact cooling. 26 of the patients were treated for a range of vascular lesions, 2 patients for facial photo-rejuvenation and 3 patients for long-term hair removal. Clinical photographic assessments were recorded in two phases and the treating practitioners were asked to record and immediately report any adverse or unexpected side-effects.* ***Results****: Visual assessment for each patient treated for vascular lesions showed total clearance of the vessel without reappearance for up to 10 months. Superficial cherry hemangioma cleared after a single treatment and deeper lesions after 2 treatments. Response to the hair reduction treatment occurred 4 weeks after the first treatment. Facial photo-rejuvenation treatments yielded general skin texture and tone improvement, as well as a noticeable skin tightening effect of the wrinkles.* ***Discussion and Conclusion****: The Viora long pulse Nd:YAG laser with variable-pulse duration, Single and Multiple pulse configurations, changeable spots and contact cooling achieved remarkable results. There was notable clearing of the treated vascular lesions, with selective damage of the vascular lesions without significant discomfort or non-selective damage to the surrounding tissue. In conclusion, the final results of the selected patients, expressed in effective and comfortable treatment modality with minimal side effects.*

INTRODUCTION

The Neodymium-YAG (Yttrium-Aluminium-Garnet) laser is a solid state laser with a crystalline rod that is grown by combining yttrium, aluminum, and garnet (YAG) and doping it with a few percent of neodymium ions [1]. Nd:YAG lasers emitting light at 1064 nm have been the most widely used laser for laser-induced thermotherapy, including ophthalmology, podiatry, oncology and esthetic cosmetic medicine. In the esthetic field, the most popular applications of long pulse Nd:YAG lasers are hair removal, treatment of vascular lesions, skin photo-rejuvenation and more. The main advantages of long pulse Nd:YAG laser compared to shorter wavelength lasers, is reduction in epidermal damage due to reduced epidermal energy absorption, reduced scattering and deeper penetration.

For hair removal application, the treatment of darker-skinned patients with acceptable results requires longer pulse duration, longer wavelength and optimum cooling. Longer wavelengths are less absorbed by melanin and therefore they are sparing epidermal melanin in dark patients. However, they are sufficiently absorbed in the pigmented hair follicle to produce hair damage [2]. Since the long-pulsed Nd:YAG lasers (1064 nm) accomplish the above criteria, it can be particularly appropriate for dark skin patients for hair removal application [3]. In addition, collateral damage to perifollicular blood vessels may play an additional role in the Nd:YAG hair removal or reduction process [4].

The non-invasive skin rejuvenation application aimed to improve aesthetic concerns caused by sun-induced or environmental skin damages [5]. Among different non-invasive techniques, the Nd:YAG laser presents the representative treatment characteristics for skin rejuvenation. This laser can lead to clinical improvements in rhytides and skin texture [6-7] as well as atrophic acne scars [8] and general skin appearance.

Finally, the use of lasers for the treatment of vascular lesions such as port wine stains began in the 70s with the green Argon laser [9]. The use of vascular lasers was further established in the 80s following the introduction of more vascular specific lasers, such as KTP laser at 532 nm [10], followed with newer laser modalities such as the long pulsed Nd:YAG laser [11]. Today, the long pulse Nd:YAG lasers are used to treat rosacea, facial telangiectasia, poikiloderma of Civatte, hemangiomas of infancy, tuberous hemangiomas, flat, and tuberous port wine stains (PWS) and leg veins [9] up to 4 mm diameter [12]. A further development of the long pulsed Nd:YAG technology has allowed the delivery of a macropulse consisting of a series of synchronized sub-pulses. This approach is believed to decrease the thermal damage collateral to the target veins, thus lowering the number of reported side effects [13]. This method was first proposed by Mordon in 1986 [14] with further study conducted by Glenn *et al*. [15]. According to the authors, in order to maintain a relatively "constant" temperature in the blood vessel with increased temperature differential between the treatment site and surrounding tissue, a non-uniform pulse sequence would be essential. Viora's new PCR™ technology stands for Pulse ConfiguRhythm, which enables the practitioner to emit the 1064 nm laser beam either via Single pulse configuration or Multiple pulse configuration which represents a three sub-pulses sequence. The aim of this study was to investigate the safety and efficacy of PCR™ technology incorporated in Viora's V-Nd:YAG handpiece.

MATERIAL AND METHODS

Case Study Group

A group of thirty-one volunteers (28 females and 3 males), in age range of 23-70 years (average age, 46 years, SD ± 14) were enrolled in this study. 26 patients were treated for different vascular lesions, including hemangiomas, telangiectasia and leg veins, 2 patients for facial photo-rejuvenation and 3 patients for long-term hair removal (3 axilla and 2 facial sites).

Handpiece Description

The treatment performed with Viora's long pulse Nd:YAG laser, 1064 nm, the V-Nd:YAG handpiece. The V-Nd:YAG handpiece utilizes Viora's proprietary PCR™ technology. PCR stands for Pulse ConfiguRhythm. The main principle of PCR™ technology is to facilitate choosing between two diverse pulse configurations: **Single** and **Multiple**. The **Single** pulse configuration represents a typical square (smooth) pulse structure, while the **Multiple** pulse configuration represents a pulse which is divided into three sub-pulses with two delays in-between. The delay allows the epidermal cells and smaller vessels to cool down between pulses while the heat is retained in the target tissue (vessels, hair follicles, etc.) resulting in selective thermal damage (the principle of thermokinetic selectivity) [16]. Therefore, the **Multiple** pulse configuration enables higher energy fluence delivery, with improved safety and deeper depth penetration.

The handpiece incorporates changeable spots with integrated TEC contact cooling, while 2mm x4mm, 3.5mm and 5.5mm spots are indicated for vascular lesions treatments and 9.5mm spot size is indicated for photo-rejuvenation and long-term hair removal.

Treatment Regimen

Patients with vascular lesions treated for 1-3 sessions with 6-12 weeks intervals (depending on the lesion size and depth). Superficial and small lesions (0.1-1 mm in diameter) treated with 2mm x 4mm spot size, usually with **Single** pulse configuration, 10-15 ms pulse duration with 180-250 J/cm^2 energy fluence. Mediums size blood vessels (1-2 mm in diameter) treated with 3.5mm spot size, with **Single** or **Multiple** pulse configuration, 15-20 ms Single pulse duration and 5-10 ms sub-pulse duration in **Multiple** pulse configuration, with 120-200 J/cm^2 energy fluence. Large size blood vessels (2-4 mm in diameter) treated with 5.5mm spot size, with **Single** or **Multiple** pulse configuration, 20-25 ms Single pulse duration and 5-10 ms sub-pulse duration in **Multiple** pulse configuration, with 90-150 J/cm^2 energy fluence (**Figure 1**). Patients with unwanted hair treated for 6 sessions on axilla and 4 treatment for facial area, with 4 weeks intervals (for both, axilla and facial treatment), 20-25 ms pulse duration and 40-50 J/cm^2 energy fluence. Finally photo-rejuvenation treatment performed every 3-4 weeks for 2-3 sessions 25 ms **Single** pulse duration and 10 ms sub-pulse duration in **Multiple** pulse configuration, with 30-50 J/cm^2 energy fluence.

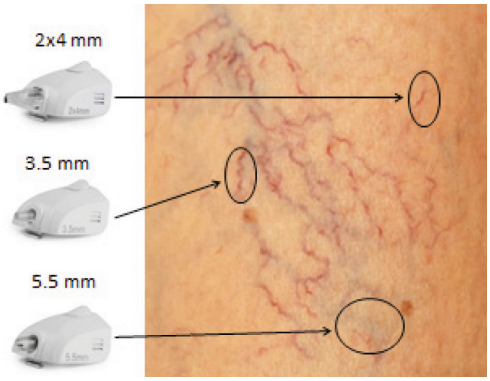

Figure 1. V-Nd:YAG spot size choice according to blood vessel diameter and depth.

Clinical Assessment

Clinical photographic assessments were recorded in two phases: (1) at baseline - prior to the first treatment and (2), at least 3 month after the final treatment. Additionally, the treating practitioners were asked to record and immediately report any adverse or unexpected side-effects.

RESULTS

Following the blood vessels treatments, darkening of the vessel and/ or erythema was observed. Treatments of deeper lesion also responded with edema along the vessel. The immediate response to light emission over cherry hemangiomas was immediate darkening of the lesion with light surrounding erythema. The side effects where limited to a burning sensation immediately post treatment which lasted up to 1 hour, and one patient attained small blisters that developed up to 24 hours post treatment on 3mm in diameter leg veins. The crusting resolved during the next 8 days without scarring or textural changes.

Following the long term hair removal and photo-rejuvenation, no side effect was recorded.

The results of visual assessment for each patient treated for vascular lesions showed total clearance of the treated vessel without reappearance, up to 10 months follow-up (**Figure 2**).

Before 10 months post 1 Treatments

Figure 2. A 44 year old female with telangiectasia before (***left***) and 10 months after 1 treatment session (***right***) with the 2mm x 4mm spot size.

Areas with different size and depth of blood vessels where treated during 2-3 separate sessions, while the largest vessels where treated during the first session, followed with treatment of smaller vessels through the subsequent treatments (as shown in **Figure 1**).

In most cases of cherry hemangioma, the total clearance of the lesion was achieved from a single treatment. However, deeper lesions where treated twice, since single treatments achieved only partial clearance, as shown in **Figure 3**.The lesions were treated with any of the three vascular spots, 2mm x 4mm, 3.5mm or 5.5mm, depending on the lesion diameter and depth.

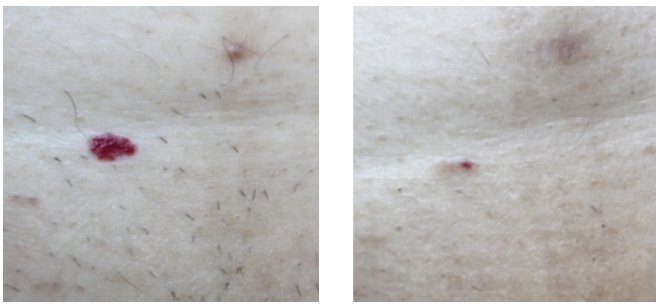

Before 9 weeks post 1 Treatments

Figure 3. A 44 year old female with cherry hemangioma before (***left***) and 9 weeks after 1 treatment session (***right***) with the 5.5mm spot size.

The response to the hair reduction treatment, occurred 4 weeks post first treatment, in both axilla and facial treatment areas. The visual photograph assessment was taken before shaving, and estimated reduction was approximately 70% post 6 axilla treatments (**Figure 4**) and about 85% post 4 facial treatments.

Before Post 5 Treatments

Figure 4. A 28 year old female (Fitzpatrick VI) with unwanted axilla hair before (***left***) and after 5 treatment sessions (***right***) with the 9.5mm spot size. Both pictures where taken before shaving.

During facial photo-rejuvenation treatments, patients with mild photoaging skin were treated with Single pulse configuration with 1-2 passes with clear end-point of transient erythema. However, patients with severe photoaging symptoms, were treated with Multiple pulse configuration and usually 3-4 passes were needed to achieve the desirable end-point. In addition to general skin texture and tone improvement, a noticeable skin tightening effect and wrinkle reduction was observed (**Figure 5**).

Before Post 1 Treatments

Figure 5. A 68 year old female with photoaged skin before (***left***) and after one treatment session (***right***) with the 9.5mm spot size.

DISCUSSION & CONCLUSIONS

Viora's long pulse Nd:YAG laser with variable-pulse duration, **Single** and **Multiple** pulse configurations, changeable spots (2mm x 4mm, 3.5mm' 5.5mm and 9.5 mm) and contact cooling achieved remarkable results (**Figures 2–5**). There was excellent clearing of the treated vascular lesions, especially for venules and veins in the 1–4 mm range. What was most notable with the V-Nd:YAG practice is its ability to selectively damage the vascular lesions without significant discomfort or non-selective damage to the surrounding tissue. This can be contributed to the contact cooling integrated within the changeable spots. The results were also obtainable to dark skin patients where cooling is even more essential to protect the pigmented epidermis [2]. In addition, as in the direct-contact working method with large reticular veins, a minimal pressure is applied against the skin, and the total diameter of the vein minimizes, which allows greater penetration and less total heat accumulation by reducing the target size. This also contributes to a reduction in pain level [9].

The high-selectivity response achieved with the V-Nd:YAG treatment can be also contributed to the variety of treatment parameters and spots sizes available. Several factors such as the size of vessels, depth of the lesion, area of body treated and type of lesion affect the absorption of laser. Vessels with different diameters have diverse TRT (thermal relaxation time) and therefore, require an adjustable pulse duration range [17]. In addition, Nd:YAG systems are able to control depth of penetration through appropriate spot selection [10]. The larger spot sizes are needed for thicker or deeper ones such as tuberous hemangiomas or PWS, leg veins [9]. Together with variable pulse durations, we can fine-tune the treatment to selected vessel to cater for multiple variables.

But not less importantly, using the PCR technology, with two different pulse configuration (**Single** and **Multiple**), further contributes to treatment selectivity and safety. While treating deep and large blood vessels, the **Multiple** pulse configuration becomes most beneficial. According to Mordon *et al*. research [18], the process of methemoglobin formation, initiated with the first sub-pulse, changes the optical condition of hemoglobin absorption, making the thermal effect of the subsequent sub-pulses more effective. Here, the total energy delivered is much higher than can be delivered in a single pulse, since this incident energy heat the target vessels progressively. Having relatively long intervals between the sub-pulses permits the use of high fluences but with a reduction in pain and minimal side effects due to lowered creation of secondary thermal damage to the epidermis.

The treatments of facial photo-rejuvenation in this study showed significant clinical outcomes not only in the skin appearance, but in highly noticeable skin tightening effect and wrinkles reduction (**Figure 5**). Although the group size in this study was limited, our results are similar to those published with other Nd:YAG systems. Compared to other light sources, the 1064 nm laser concentrates the heat energy more deeply under the same irradiation conditions, because of the relatively high penetrability [19-20]. This can significantly contribute to deep dermal heating and consequently to collagen remodeling and fibroblast stimulation. The advantage of skin tightening and rejuvenation with deep penetration of 1064 nm is that the epidermal temperature is much lower with larger temperature variations in dermis layer with active fibrous formations [21].

Although, the 9.5mm spot size of V-Nd:YAG laser limits the hair removal treatment to small treatment zones, such as axilla, bikini and face, the significant response to the laser occurred 4 weeks post the first treatment. The estimated reduction of 70% and 85% in hair growth post 6 axilla treatments (**Figure 4**) and 4 facial treatments, respectively, indicates that the treatment is as effective as with other case groups and longer follow-up periods [2, 22-23].

In conclusion, the final results of the selected patients, expressed in effective and comfortable treatment modality with minimal side effects. This is due to strong epidermal contact cooling, varied spots sizes and pulse duration and two pulse configurations available in Viora's PCR™ technology.

REFERENCES

1. Wolfe WG, Cole PH, Sabiston DC. Experimental and clinical use of the YAG laser in the management of pulmonary neoplasms. Ann Surg. 1984 May; 199(5): 526–531.
2. Ismail SA. Long-pulsed Nd:YAG laser vs. intense pulsed light for hair removal in dark skin: a randomized controlled trial. Br J Dermatol. 2012 Feb;166(2):317-21.
3. Bhatt N, Alster TS. Laser surgery in dark skin. Dermatol Surg. 2008 Feb;34(2):184-94; discussion 194-5.
4. Adrian RM. Vascular mechanisms in laser hair removal. J Cutan Laser Ther. 2000;2:49–50.
5. Munavalli GS, Weiss RA and Halder RM. Photoaging and nonablative photorejuvenation in ethnic skin. Dermatol Surg. 2005 Sep;31 (9 Pt 2):1250-60; discussion 1261.
6. Babilas P, Schreml S, Eames T, Hohenleutner U, Landthaler M and Hohenleutner S. Experience with non-ablative fractional photothermolysis with a dualmode laser device (1,440/1,320 nm): no considerable clinical effect on hypertrophic/acne scars and facial wrinkles. Lasers Med Sci. 2011 Jul;26(4):473-9.
7. Lee DC, Hu S, Chen MC, Shih YC, Huang YL and Lee SH. Skin rejuvenation with 1,064 nm Qswitched Nd:YAG laser in Asian patients. Dermatol Surg. 2009 Jun;35(6):929-32.
8. Keller R, Belda Ju ´nior W, Valente NY and Rodrigues CJ. Nonablative 1,064 nm Nd:YAG laser for treating atrophic facial acne scars: histologic and clinical analysis. Dermatol Surg. 2007 Dec;33(12): 1470-6.
9. Srinivas CR, Kumaresan M. Lasers for vascular lesions: Standard guidelines of care. Dermatosurgery Specials. 2011; 77(3):349-368.
10. Anderson RR, Parish JA. Selective photothermolysis: Precise microsurgery by selective absorption of pulse radiation. Science 1983;220:524-7.
11. Nouri K. Laser treatment of acquired and congenital vascular lesions. Emedicine 2006 Sept 18. www.emedicine.com/derm/topic518.htm
12. Sadick NS. Long-term results with a multiple synchronizedpulse 1,064 nm Nd:YAG laser for the treatment of leg venulectasias and reticular veins. Dermatol Surg 2001;27:365–369.
13. Derbyshire GJ, Bogen DK, Unger M. Thermally induced optical property changes in myocardium at 1.06 microns. Lasers Surg Med 1990;10(1):28–34.

14. Mordon S, et al. Comparative study of pulsed and CW ND:YAG laser coagulation. in 8th IEEE/IFMBE Annual Conference. Fort Worth: IEEE; 1986.
15. Glenn TN, Rastegar S, Jacques SL. Finite element analysis of temperature controlled coagulation in laser irradiated tissue. IEEE Trans Biomed Eng 1996;43(1):79–87.
16. Dierickx CC, Casparian JM, Venugopalan V, Farinelli WA, Anderson RR. Thermal relaxation of port-wine stain vessels probed in vivo: the need for 1-10-millisecond laser pulse treatment. J Invest Dermatol. 1995;105(5):709-714.
17. Rothfleisch JE, Kosmann MK, Levine VJ, Ashinoff R. Laser treatment of congenital and acquired vascular lesions: update on lasers: A review. Dermatol Clin 2002;20:1-18.
18. Mordon S, Brisot D, Fournier N. Using a "Non uniform pulse sequence" can improve selective coagulation with a Nd:YAG laser (1.06 mm) thanks to met-hemoglobin absorption: A clinical study on blue leg veins. Lasers Surg Med 2003;32:160–170.
19. Rogachefsky AS, Silapunt S and Goldberg DJ. Nd:YAG laser (1064 nm) irradiation for lower extremity telangiectases and small reticular veins: efficacy as measured by vessel color and size. Dermatol Surg. 2002 Mar;28(3):220-3.
20. Alora MB and Anderson RR. Recent developments in cutaneous lasers. Lasers Surg Med. 2000;26(2):108-18.
21. Lee JH, Park SR, Jo JH, Park SY, Seo YK, Kim SM. Comparison of epidermal/dermal damage between the long-pulsed 1064 nm Nd:YAG and 755 nm alexandrite lasers under relatively high fluence conditions: quantitative and histological assessments. Photomed Laser Surg. 2014 Jul;32(7):386-93.
22. Ghaly NR. Evaluation of Alexandite laser, Nd:YAG laser and Intense pulsed light for axillary hair removal: A prospective randomized controlled trial. Tanta Med Sci J 2006: 1(1):26-36.
23. Tanzi EL, Alster TS. Long-Pulsed 1064-nm Nd:YAG Laser-Assisted Hair Removal in All Skin Types. Dermatol Surg 2004;30:13–17.

VIORA